









INTERNATIONAL JOURNAL OF MEDICAL ARTS



Volume 5, Issue 8, August 2023

<https://ijma.journals.ekb.eg/>




Print ISSN: 2636-4174

Online ISSN: 2682-3780



Available online at Journal Website
<https://ijma.journals.ekb.eg/>
 Main Subject [Dermatology]



Original Article

Efficacy of Isotretinoin in The Management of Enlarged Facial Pores in Moderate and Severe Acne Vulgaris Patients

Waleed Ibrahim Ahmed Gaber *, Abd Al Shakour Abd Al Hafiz Abd Al Wahed,
 Mohamed Ismail Kamel

Department of Dermatology, Venereology and Andrology, Faculty of Medicine, Al-Azhar University, Cairo, Egypt

ABSTRACT

Article information

Received: 11-08-2023

Accepted: 13-09-2023

DOI: 10.21608/IJMA.2023.228728.1769.

*Corresponding author

Email: drwaleedgaber1@gmail.com

Citation: Gaber WIA, Abd Al Wahed AA, Kamel MI. Efficacy of Isotretinoin in The Management of Enlarged Facial Pores in Moderate and Severe Acne Vulgaris Patients. IJMA 2023 August; 5 [8]: 3548-3553. doi: 10.21608/IJMA.2023.228728.1769.

Background: A multitude of treatment options have been used in dealing with enlarged facial pores. However, there is a lack of studies assessing the effectiveness of oral isotretinoin, which is commonly used to treat acne, as a treatment option for enlarged facial pores in such patients.

Aim of the work: To assess the effectiveness of oral isotretinoin in reducing the size of enlarged facial pores in patients with moderate and severe acne vulgaris.

Patients and Methods: Forty cases with moderate and severe acne vulgaris, characterized by the presence of multiple to numerous inflammatory papules, pustules, nodules, and scarring, as well as enlarged facial pores, were prescribed oral isotretinoin. The daily dosage ranged from 0.5 to 1.0 mg/kg/day, with a total cumulative dose of 120 mg/kg administered over a 6-month treatment period. For each patient, dermoscopic photos were taken of the enlarged facial pores located on the tip of the nose, where sebum production is high and the pores are clinically visible. These photos were captured both before and after the 6 months of treatment. The total surface area of all facial pores was measured using Fiji software, and a comparison was made between the measurements before and after treatment to determine any differences.

Results: All of the treated patients exhibited a statistically significant decrease in the size of their facial pores after treatment [$0.46 \pm 0.2 \text{ mm}^2$], as compared to the size of their facial pores before treatment [$0.67 \pm 0.3 \text{ mm}^2$], with a p-value < 0.05.

Conclusion: In our study, Isotretinoin has been demonstrated to be a safe and effective treatment modality for managing enlarged facial pores in patients with moderate and severe acne vulgaris.

Keywords: Isotretinoin; Dermoscopy; Acne Vulgaris.



This is an open-access article registered under the Creative Commons, ShareAlike 4.0 International license [CC BY-SA 4.0] [<https://creativecommons.org/licenses/by-sa/4.0/legalcode>].

INTRODUCTION

Enlarged facial pores are one of the most common complaints among patients with oily skin. These pores correspond to the visible openings of the sebaceous glands and are more pronounced in patients with acne vulgaris, oily skin, decreased skin elasticity, and increased pore volume. Several contributing factors have been found to affect the size of pores in individuals with acne vulgaris, including sebum production, skin elasticity, pore volume, and ethnicity [1].

Enlarged facial pores can be visualized using polarized light dermoscopy, which shows different sizes of the sebaceous gland follicular openings filled with yellow-whitish plugs that represent the produced sebum [2].

Isotretinoin is considered the most effective treatment for moderate to severe acne vulgaris. Its mechanism of action involves reducing sebum production, normalizing follicular hyperkeratinization, reducing the population of Cutibacterium acnes, and modulating the inflammatory cytokines involved in the pathogenesis of acne vulgaris [3].

Limited data are available about the therapeutic role of oral isotretinoin in the management of enlarged facial pores in patients with acne vulgaris. Therefore, the objective of the current research was to assess the safety and efficacy of isotretinoin in managing enlarged facial pores in a cohort of patients with moderate to severe acne vulgaris.

PATIENTS AND METHODS

This single-arm interventional study involved 40 cases [33 females and 7 males] with moderate to severe acne vulgaris and enlarged facial pores. The study was conducted in the Dermatology Department of Al-Hussein University Hospital, Faculty of Medicine, Al-Azhar University, from September 2020 to March 2021. Cases that had received a previous course of isotretinoin, pregnant females or females seeking pregnancy, as well as patients with contraindications to isotretinoin, were excluded from the study.

Prior to participating in the research, every case was informed about the treatment plan, and written consent was obtained from each participant.

Prior to treatment, all cases in the study underwent a thorough clinical examination to assess inclusion and exclusion criteria. Patients with moderate to severe acne vulgaris, described as multiple to numerous inflammatory papules, pustules, nodules, and scarring, were included in the study. All patients received oral isotretinoin at a daily dose of 0.5 to 1.0 mg/kg/day for a total cumulative dose of 120 mg/kg over a treatment period of 6 months [4].

At baseline and after 6 months of treatment, dermoscopic examinations were performed to assess facial pores, and photographs were taken for each patient. Dermoscopic photos of the enlarged facial pores over the tip of the nose [an area with clinically visible pores and high sebum production [5]] were captured before and after the 6-month treatment period using a Sony Cyber-shot DSC-T90 camera.

Fiji software, which is used to assess microscopic structures in digital images [6], was used to analyze the captured images. All facial pores in the dermoscopic field were measured for their total surface area. The total surface area of the pores before and after treatment was compared to determine any differences.

Statistical analysis: The data were analyzed using version 24 of the Statistical Program for Social Science [SPSS]. Categorical data were expressed as mean \pm standard deviation [SD], while qualitative data were presented as frequency and percentage. The Mann-Whitney U test was used to compare two means, and the chi-square test was carried out to compare qualitative data. The Pearson correlation coefficient was used to evaluate the degree of relationship between two variables. A P-value of less than 0.05 was considered significant.

RESULTS

The demographic data of the examined cohort is presented in table [1]. The patients with acne in the present study had an average age of 19.6 ± 3.7 years, with females comprising the majority [82.5%]. The mean duration of acne was 2.14 ± 1.2 years.

The baseline data regarding the surface area of facial pores showed that the duration of acne vulgaris did not correlate with the surface area of facial pores [$r=0.25$, $P=0.117$]. However, the surface area of facial pores was significantly larger in males, with a mean of 0.92 ± 0.4 mm²,

compared to $0.62 \pm 0.28 \text{ mm}^2$ in females [P=0.025].

When evaluating the effect of oral isotretinoin therapy among the studied cohort, a significant reduction in the size of facial pores was observed after treatment [P=0.002]. A comparison between the size of enlarged facial pores before and after treatment can be seen in figure [1].

Among patients with acne, there was a significant decline in the surface area of facial pores in female cases when comparing the surface area before treatment [$0.62 \pm 0.28 \text{ mm}^2$] to the surface area after treatment [$0.44 \pm 0.21 \text{ mm}^2$] [P=0.007]. However, in male patients, there was no statistically significant variance in the surface area of facial pores before treatment [$0.92 \pm 0.4 \text{ mm}^2$] when compared to the surface area after treatment [$0.58 \pm 0.19 \text{ mm}^2$] [P=0.074].

Table [1]: Description of demographic data for all examined cases

Variables		Studied patients [n = 40]
Age [years]	Mean \pm SD	19.6 \pm 3.7
	Min - Max	15 - 27
Sex	Male	7 [17.5%]
	Female	33 [82.5%]
Acne duration [years]	Mean \pm SD	2.14 \pm 1.2
	Min - Max	0.5 - 5

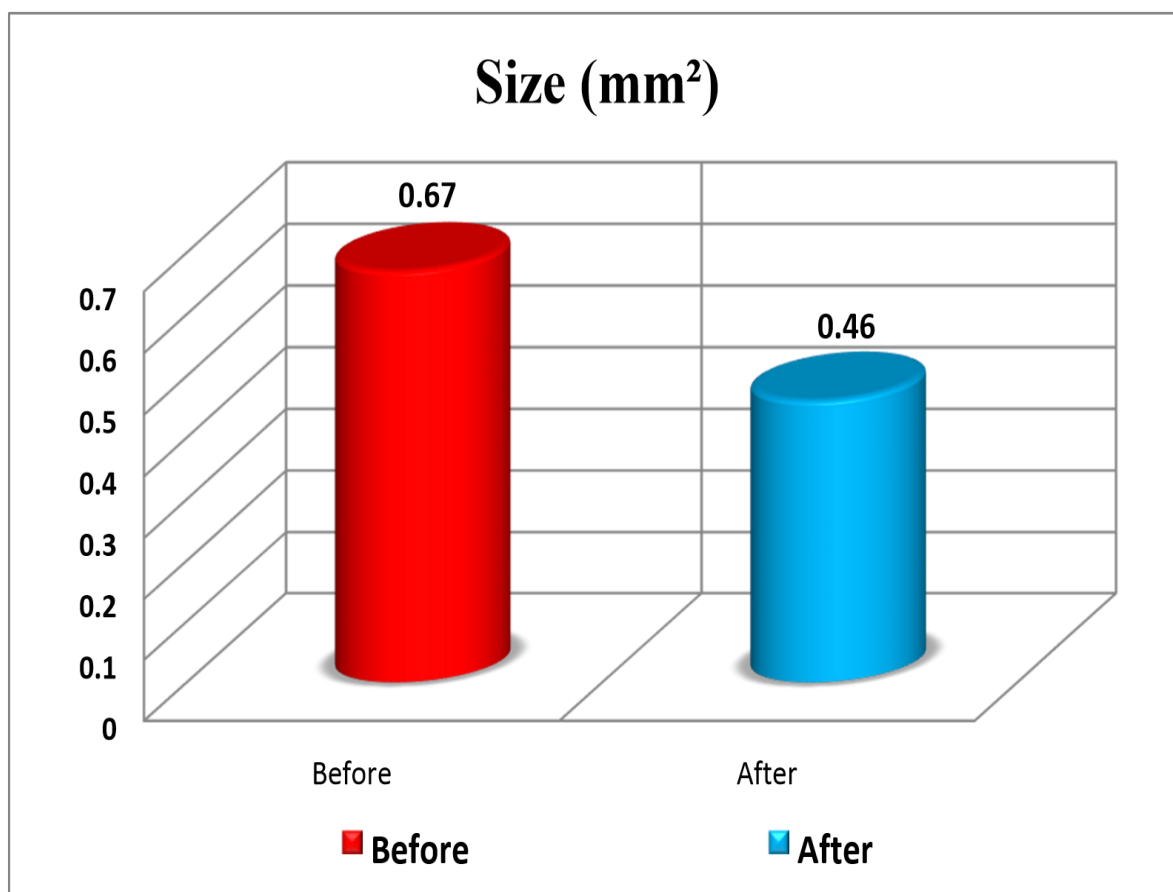


Figure [1]: Comparison of facial pore size before and after treatment

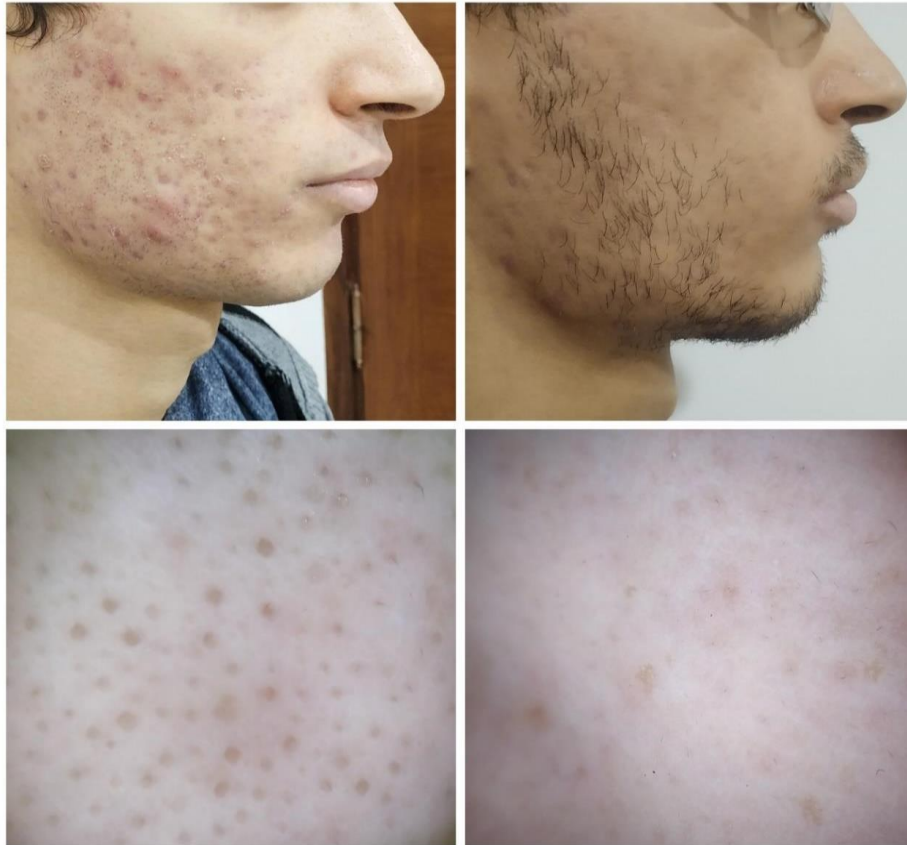

Figure [2]: 22 years old male patient with severe acne of 3 years duration, after treatment there was marked reduction in the sizes of the enlarged facial pores which can be seen by dermoscopy [Left: Before / Right: After].

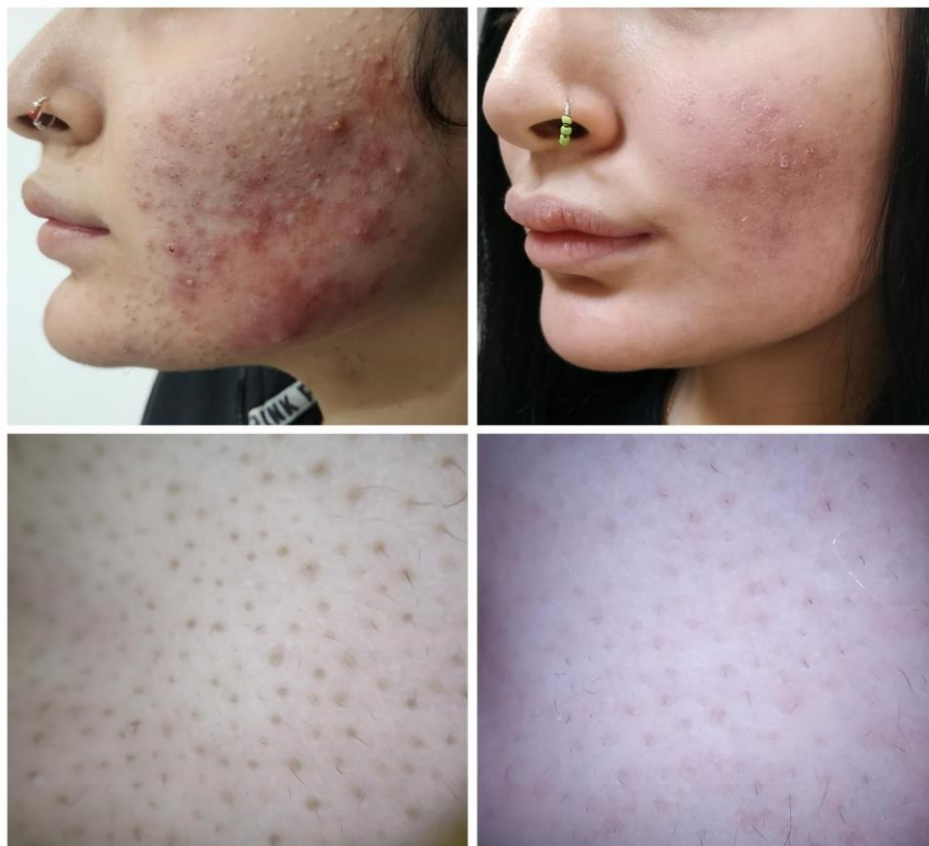

Figure [3] :21 years old female patient with severe acne of 6 months duration, after treatment there was marked reduction in the sizes of the enlarged facial pores which can be seen by dermoscopy [Left: Before / Right: After].

DISCUSSION

Although a few studies have assessed the therapeutic role of oral isotretinoin in cutaneous aging^[7, 8], limited data is available regarding its effectiveness in treating enlarged facial pores in patients with acne vulgaris. Therefore, the objective of the current research was to evaluate the safety and efficacy of oral isotretinoin in managing enlarged facial pores in a cohort of patients with moderate to severe acne vulgaris

In the present research, dermoscopy was utilized to assess the sizes of enlarged facial pores by measuring their total surface area before and after treatment using Fiji software, which assesses microscopic structures in digital images^[6]. Previous studies^[9, 10] have shown that dermoscopy can be a reliable tool for evaluating facial pore size. In their studies, a dermoscopic video camera was used to capture footage of the facial pore structure, and the size was assessed using an image analysis program. They concluded that facial pore size correlated with higher sebum output levels^[9, 10].

The baseline data from the current study revealed that male patients had larger pore sizes than female patients, and this difference was statistically significant [P= 0.025]. Similarly, **Roh et al.**^[9] reported larger facial pore sizes in males. This observation could be attributed to the fact that androgens in male patients cause more sebum production, leading to greater distension of facial pores. Higher sebum output levels were found to correlate with larger pore sizes^[5, 9].

In the current study, treatment with oral isotretinoin in moderate and severe acne patients with enlarged facial pores resulted in a statistically significant overall reduction in facial pore size [p-value < 0.05]. These changes can be observed using dermoscopy in figures [2] and [3]. An earlier study by **Geissler et al.**^[11], which evaluated the role of isotretinoin in controlling seborrhea, showed a 64% decrease in sebum production as evaluated with Sebutape. In their study, patients used different dosing regimens of 5 mg/d, 2.5 mg/d, or 2.5 mg 3x weekly over a 6-month period, and they concluded that better results were obtained with higher doses

Two previous studies have evaluated the therapeutic role of isotretinoin in cutaneous aging. **Hernandez Perez et al.**^[7] evaluated the

effect of a combination treatment of isotretinoin [10-20 mg, 3 times per week for 2 months] combined with rejuvenation techniques, and found a significant clinical improvement in the appearance of enlarged facial pores as a part of the signs of cutaneous photoaging. Similar results were observed by **Rabello-Fonseca et al.**^[8] when evaluating the effectiveness of oral isotretinoin [10-20 mg, 3 times per week for 3 months].

Interestingly, in the current study, male patients did not show a statistically significant reduction in facial pore size after treatment [P=0.074], unlike female patients [P=0.007]. The lower response of male patients to oral isotretinoin in this study could be due to the fact that males had significantly larger pore size, which may reflect a higher sebum output level. Furthermore, this data could be attributed to the smaller sample size of male patients [17.5%], indicating the need for further studies with a larger sample size of male patients.

To the best of our knowledge, this is the first study to examine the effectiveness of isotretinoin in treating enlarged facial pores in a cohort of individuals with moderate and severe acne vulgaris.

The study has several limitations, including the absence of a control group, a short follow-up period, a smaller sample size of male patients, and an overall small sample size

Conclusion: Oral isotretinoin may be a safe and effective therapy for managing enlarged facial pores in cases of moderate to severe acne vulgaris. However, further studies with different dosing regimens and larger sample sizes are needed to validate the safety and effectiveness of oral isotretinoin for managing enlarged facial pores.


Authorship: The outline and entire manuscript were drafted, reviewed, and revised by all writers, who also decided to publish it.

Conflict of interest: None of the writers have conflicts of interest.

Funding: This research received no pharmaceutical or funding agency support.

REFERENCES

1. Dong J, Lanoue J, Goldenberg G. Enlarged facial pores: an update on treatments. *Cutis*. 2016 Jul;98[1]:33-6. PMID: 27529707.
2. Kelati A, Aqil N, Mernissi FZ. Dermoscopic Findings and Their Therapeutic Implications in Trichostasis Spinulosa: A Retrospective Study of 306 Patients. *Skin Appendage Disord*. 2018 Oct;4[4]:291-295. doi: 10.1159/000486541.
3. Costa CS, Bagatin E, Martimbianco ALC, da Silva EM, Lúcio MM, Magin P, Riera R. Oral isotretinoin for acne. *Cochrane Database Syst Rev*. 2018 Nov 24;11[11]:CD009435. doi: 10.1002/14651858.CD009435.pub2.
4. Zaenglein AL, Pathy AL, Schlosser BJ, Alikhan A, Baldwin HE, Berson DS, *et al*. Guidelines of care for the management of acne vulgaris. *J Am Acad Dermatol*. 2016 May;74[5]:945-73.e33. doi: 10.1016/j.jaad.2015.12.037.
5. Kim BY, Choi JW, Park KC, Youn SW. Sebum, acne, skin elasticity, and gender difference - which is the major influencing factor for facial pores? *Skin Res Technol*. 2013 Feb;19[1]:e45-53. doi: 10.1111/j.1600-0846.2011.00605.x.
6. Schindelin J, Arganda-Carreras I, Frise E, Kaynig V, Longair M, Pietzsch T, *et al*. Fiji: an open-source platform for biological-image analysis. *Nat Methods*. 2012 Jun 28;9[7]:676-82. doi: 10.1038/nmeth.2019.
7. Hernandez-Perez E, Khawaja HA, Alvarez TY. Oral isotretinoin as part of the treatment of cutaneous aging. *Dermatol Surg*. 2000 Jul;26[7]:649-52. doi: 10.1046/j.1524-4725.2000.99210.x.
8. Rabello-Fonseca RM, Azulay DR, Luiz RR, Mandarim-de-Lacerda CA, Cuzzi T, Manela-Azulay M. Oral isotretinoin in photoaging: clinical and histopathological evidence of efficacy of an off-label indication. *J Eur Acad Dermatol Venereol*. 2009 Feb;23[2]:115-23. doi: 10.1111/j.1468-3083.2008.02947.x.
9. Roh M, Han M, Kim D, Chung K. Sebum output as a factor contributing to the size of facial pores. *Br J Dermatol*. 2006;155[5]: 890-4. doi: 10.1111/j.1365-2133.2006.07465.x.
10. Flament F, Francois G, Qiu H, Ye C, Hanaya T, Batisse D, *et al*. Facial skin pores: a multiethnic study. *Clin Cosmet Investig Dermatol*. 2015 Feb 16;8:85-93. doi: 10.2147/CCID.S74401.
11. Geissler SE, Michelsen S, Plewig G. Very low dose isotretinoin is effective in controlling seborrhea. *J Dtsch Dermatol Ges*. 2003 Dec;1[12]:952-8. doi: 10.1046/j.1365-2303.2003.00108.x-i1.



International Journal

<https://ijma.journals.ekb.eg/>

Print ISSN: 2636-4174

Online ISSN: 2682-3780

of Medical Arts